



Case Report

A closer look at ARSA activity in a patient with metachromatic leukodystrophy



Kathleen Doherty^a, S. Barron Frazier^a, Matthew Clark^a, Anna Childers^b, Sumit Pruthi^c, David A. Wenger^d, Jessica Duis^{b,*}

^a Department of Pediatrics, Vanderbilt University Medical Center, Nashville, TN, USA

^b Department of Pediatrics, Division of Medical Genetics & Genomic Medicine, Vanderbilt University Medical Center, Nashville, TN, USA

^c Department of Pediatrics, Division of Radiology and Radiological Sciences, Vanderbilt University Medical Center, Nashville, TN, USA

^d Department of Neurology, Thomas Jefferson University, Philadelphia, PA, USA

ARTICLE INFO

Keywords:

Metachromatic Leukodystrophy

Leukodystrophy

Arylsulfatase A

Lysosomal storage disease

Inborn error of metabolism

ABSTRACT

Metachromatic leukodystrophy (MLD) is an autosomal recessive lysosomal storage disease mainly caused by a deficiency of arylsulfatase A activity. The typical clinical course of patients with the late infantile form includes a regression in motor skills with progression to dysphagia, seizures, hypotonia and death. We present a case of a 4-year-old female with rapidly progressive developmental regression with loss of motor milestones, spasticity and dysphagia. MRI showed volume loss and markedly abnormal deep white matter. Enzymatic testing in one laboratory showed arylsulfatase A activity in their normal range. However, extraction of urine showed a large increase in sulfatide excretion in a second laboratory. Measurement of arylsulfatase A in that laboratory showed a partial decrease in arylsulfatase A activity measured under typical conditions (about 37% of the normal mean). When the concentration of substrate in the assay was lowered to one quarter of that normally used, this individual had activity < 10% of controls. The patient was found to be homozygous for an unusual missense mutation in the arylsulfatase A gene confirming the diagnosis of MLD. This case illustrates the importance of careful biochemical and molecular testing for MLD if there is suspicion of this diagnosis.

1. Introduction

Metachromatic leukodystrophy (MLD) (OMIM # 250100) is an autosomal recessive lysosomal storage disease with a prevalence of approximately 0.6–1.9 per 100,000, which arises from deficient activity of the enzyme arylsulfatase A (ARSA) (EC 3.1.6.8) [5]. Less commonly, a deficiency in sphingolipid activator protein, saposin B, is the cause. ARSA is responsible for the degradation of sulfatides, a major component of myelin in the nervous system. In MLD, excess sulfatides accumulate in the central and peripheral nervous systems as well as other visceral organs resulting in a spectrum of clinical disease.

Clinical manifestations of MLD vary based on functionality of the ARSA enzyme. Late Infantile onset is generally associated with homozygous or compound heterozygous null alleles of the ARSA gene resulting in a rapid accumulation of sulfatides and earlier onset of disease with rapid progression [3]. Patients typically present with regression of motor skills, gait difficulties, ataxia and weakness within the first 3 years of life [5]. The disease is progressive and patients develop

dysphagia and feeding intolerance, seizures, hypotonia, and peripheral neuropathy. Patients with late infantile MLD die at a mean age of about 4 years. Individuals with juvenile and adult onset have a variety of mutations in the ARSA gene (OMIM # 607574) that must result in some residual ARSA activity explaining their later onset and the longer progression of disease. Juvenile patients typically present between 3 and 16 years of age with deterioration in intellectual performance along with behavioral difficulties [5]. These individuals are usually compound heterozygotes and have one null allele, resulting in no enzyme activity, and one allele with a mutation that results in some residual ARSA activity. Adult patients often present with a decrease in intellectual capabilities, psychiatric issues and abnormal behavior. Individuals with adult onset disease typically have two mutations that result in some residual enzyme activity [1,3,4]. The clinical course is slower than the late infantile and juvenile forms. Neurological symptoms can include gait disturbance, ataxia, seizures and peripheral neuropathy.

The diagnosis of MLD has traditionally been made based on a

* Corresponding author at: Vanderbilt University Medical Center, Division of Medical Genetics & Genomic Medicine, DD2205 Medical Center North, Nashville, TN 37232, USA.

E-mail address: Jessica.duis@vanderbilt.edu (J. Duis).

<https://doi.org/10.1016/j.ymgmr.2019.100460>

Received 12 December 2018; Received in revised form 5 February 2019; Accepted 5 February 2019

Available online 20 February 2019

2214-4269/© 2019 The Authors. Published by Elsevier Inc. This is an open access article under the CC BY-NC-ND license

(<http://creativecommons.org/licenses/by-nc-nd/4.0/>).

combination of clinical suspicion, diagnostic imaging along with biochemical and genetic testing. MRI findings include bilateral symmetric abnormal T2 signal hyperintensities indicating white matter change. The characteristic “leopard skin sign” or “tigroid pattern” results from alternating stripes of bright demyelinated periventricular white matter [8]. Measurement of low ARSA activity as part of a screen for lysosomal storage disorders may result in a presumptive diagnosis. However, ARSA activity will be normal if the patient has a deficiency of saposin B. Also, ARSA activity can be low in individuals who do not have MLD if they have two copies of the so-called pseudodeficiency (Pd) allele or one copy of the Pd allele with an MLD-causing mutation on their other allele. ARSA activity will be low in individuals with multiple sulfatase deficiency (MSD). In patients with MSD the activities of other sulfatases will also be low. The excretion of sulfatides in the urine is a definitive test to confirm the diagnosis of MLD, whether caused by defects in ARSA or saposin B. Unaffected individuals do not excrete any detectable levels of lipid. However, it is also excreted in patients with MSD along with glycosaminoglycans. Low ARSA activity and sulfatide excretion in the urine followed by the finding of disease-causing mutations in the ARSA gene usually complete the diagnosis of MLD. However, often physicians send blood for an enzymatic testing panel to screen for a storage disorder, including MLD, and normal results may not prompt additional testing. We present a case of a patient with a classic presentation of MLD, who had initial enzymatic testing in one laboratory that reported ARSA activity in the normal range. Further testing in another laboratory showed a large excretion of sulfatides in the urine and lower than normal ARSA activity which lead to additional enzymatic testing and molecular analysis that revealed a homozygous variant of unknown significance in the ARSA gene. While the diagnosis of MLD is not difficult in an experienced laboratory, there are caveats that require careful consideration.

2. Clinical report

A 4-year-old female was evaluated in a primary care clinic to establish care and to discuss poor feeding. The patient and her family had moved one month before from Kenya to the United States. The family recalls that the patient was developing normally until the age of 30 months. At that time, she developed a febrile illness for three days. The mother took the patient to a health clinic during this time where she was given an unknown medicine for a diagnosis of malaria. She returned to her normal state of health, but within one to two weeks she began to have difficulty walking. Four months later, the patient had lost the ability to sit or walk independently or catch a ball. Due to her limited function, she began to lose weight and developed contractures in her extremities. One year after her initial illness, at approximately three and a half years old, the patient no longer was able to communicate verbally, support her head independently, or tolerate solid food in her diet. Her diet consisted solely of milk, which progressively became harder to administer due to choking and gagging.

The patient was full-term at birth and had no previous medical history, medications, or known allergies. She had received age-appropriate vaccinations in Kenya. A maternal aunt died at birth but the etiology is unknown; otherwise, there was no family history of genetic conditions, developmental regression, or autoimmune disease. There were no similar episodes of symptoms in their Kenyan community. Her older sibling who is six years old is healthy and developmentally appropriate.

On physical examination, the patient was severely malnourished (weight < 0.01 percentile) with diffuse truncal hypotonia and hypertonicity in her extremities. She was able to orient towards stimuli and had a social smile. Her musculoskeletal exam was pertinent for contractures of her ankles with global muscle atrophy. She had significant head lag and was unable to support herself in the sitting position.

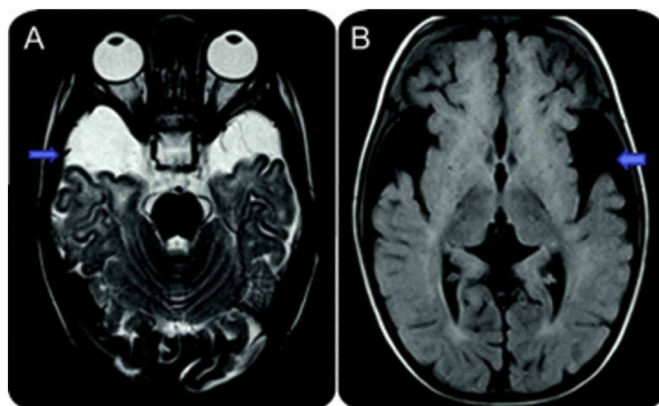


Fig. 1. Metachromatic leukodystrophy. (a) T2-weighted MR image at the level of central semiovale demonstrates bilateral confluent areas of hyperintense signal in the periventricular white matter with classic sparing of the subcortical U fibers. Also seen are linear and punctate hypointense foci, a finding that suggests sparing of the white matter, also referred to as tigroid or leopard skin appearance. (b) T2-weighted MR image at the level of posterior fossa demonstrates abnormal hyperintense signal within cerebellar white matter as well.

3. Methods and results

Due to her severe cachexia and failure to thrive, the patient was admitted to the hospitalist service for further nutritional support and further evaluation of her developmental regression. Neurology and genetics were consulted on admission to assist with diagnostic management. Both services recommended a broad laboratory workup and MRI to evaluate for a possible neurodegenerative condition.

MRI of the brain demonstrated markedly abnormal deep white matter in a symmetric predominant confluent periventricular distribution with involvement of the dentate nuclei, cerebellar white matter and descending corticospinal tracts (Fig. 1). Given the clinical history, the radiologists felt that the imaging was most consistent with MLD versus Krabbe disease or a mitochondrial disorder. Shortly after imaging was completed, blood was sent to one laboratory for testing, and ARSA activity was reported as 82 nmol/h/mg protein with values > 62 nmol/h/mg protein being normal. The conclusion was that this individual did not have MLD or MSD. Urine and blood was then sent to the laboratory of one of the authors (DAW) for testing. Initially a partial deficiency of ARSA activity was measured (37% of the normal mean of 71 nmol/h/mg protein) using the typical assay conditions using nitrocatechol sulfate (10 mM in the presence of 10% sodium chloride and acetate buffer 0.5 M, pH 5.0 and 0.25 mM sodium pyrophosphate) [9]. The activities of seven other lysosomal enzymes including galactocerebrosidase to rule out Krabbe disease and arylsulfatase B to rule out MSD were normal. A sample of urine was requested to see if sulfatides were being excreted. As shown on Fig. 2, the patient was excreting large amounts of sulfatides similar to other patients with MLD. It was possible that this individual from Kenya could have unusual mutations that result in lowish ARSA activity under typical conditions but much lower ARSA activity compared to “controls” if the substrate concentration was lowered, a so-called Km mutation. When the nitrocatechol sulfate concentration was lowered to one-quarter of that stated above (2.5 mM), this individual had an ARSA value of 6.0 nmol/h/mg protein compared to 58.6 nmol/h/mg protein for six controls. This value, about 10% of controls, is consistent with other patients confirmed to have MLD. Therefore, at the lower substrate concentration the deficiency of ARSA activity is more obvious indicating that when higher substrate concentrations are used the effect of the missense mutation can be partially overcome.

With the diagnosis of MLD confirmed by sulfatide excretion and low ARSA activity, mutation analysis on the ARSA gene was performed. Analysis was done using next-generation sequencing (NGS) technology

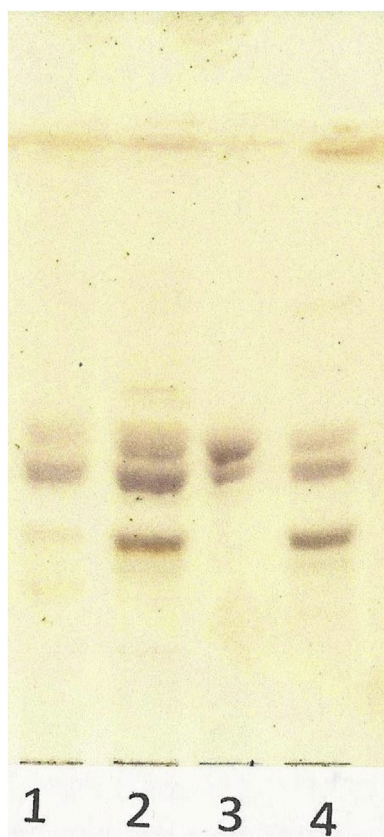


Fig. 2. Thin layer chromatography of lipid extracts of urine samples. Urine from two individuals with confirmed MLD and this patient were extracted as described previously [7]. Of note, unaffected individuals do not exhibit detectable levels of lipid within their urine sample. 1) juvenile MLD patient who received bone marrow transplantation; 2) juvenile MLD patient who did not receive bone marrow transplantation; 3) standard brain sulfatides (Sigma); 4) patient described in this manuscript. Aliquots were spotted on a silica gel thin layer chromatography plate. The plate was run in chloroform-methanol-water (75–25–3.5 ml by volume) until 2 cm from the top. After drying the plate it was sprayed with orcinol solution and heated at 100 °C for 10 min.

with a read depth of 1845 ×. Both full gene sequencing and deletion/duplication analysis were performed for *ARSA* as well as 13 additional genes related to similar phenotypes (including Neuronal Ceroid Lipofuscinoses, Metachromatic Leukodystrophy, and Niemann-Pick Disease Type C). Mutation analysis showed that this patient was homozygous for a c.449C > G mutation resulting p.Pro150Arg. Because this was considered to be a variant of unknown significance, additional technology was not used for confirmatory analysis. Note: there are two numbering systems for the *ARSA* cDNA and codons. The one used here is six nucleotides longer than the original numbering system resulting in the codons being two amino acids longer. It is considered a variant of unknown significance although it was previously found homozygous in a 1 year, 3-month-old Arabic female with late infantile MLD [4]. However in that patient, the p.Pro150Arg mutation was found in cis with the common Pd allele. The patient described herein did not have the Pd allele. A different mutation at the same codon changing the Pro150 to Leu (formerly p.Pro148Leu) has been reported in individuals with MLD [6], possibly pointing to the importance of the proline at that position.

4. Discussion

Our case highlights the importance of index of suspicion, both with respect to the clinician's evaluation of the patient and the laboratory

diagnostic work up. In this case, initial enzymatic testing was reported as normal, but the clinical and neurodiagnostic evaluation indicated more laboratory testing was indicated. When blood and urine were sent to a different laboratory, a partial deficiency of *ARSA* activity was found pointing to the need for additional testing. The finding that the patient excreted a large amount of sulfatide in urine indicated that a diagnosis of MLD was a strong possibility. It is known that certain missense mutations, changing an amino acid, may affect the way the enzyme handles the substrate. With some mutations, the activity is completely knocked out, leaving little or no residual activity, but in some cases the amino acid change may make the enzyme work less efficiently. This may be partially overcome by raising the substrate concentration. At lower concentrations of substrate, the effect of the mutation may be more obvious. This appears to be the situation in this patient.

While biochemical studies including enzymatic testing and analyte evaluation remain a valuable tool for accurate diagnosis of patients with MLD and other genetic disorders we note that molecular studies are becoming an additional component in the diagnosis. Nearly 300 mutations have been described in the *ARSA* gene. The *ARSA* gene is located on chromosome 22q13.33 and is responsible for the coding of *ARSA*. The alleles c.465 + 1G > A, c.1283C > T and c.542 T > G are common disease variants, and are associated with a partial or total disruption of *ARSA* activity [4]. In addition to disease-causing mutations, there are additional mutations that do not result in disease when inherited as homozygous mutations or as compound heterozygous with disease-causing mutations. The common so-called Pd allele can result in quite low *ARSA* activity in the laboratory and can result in an erroneous diagnosis. However, individuals with one or two copies of the Pd allele and no disease-causing mutations on at least one allele do not excrete sulfatides. It appears that approximately 10–15% of normal *ARSA* enzymatic activity is sufficient to hydrolyze the turnover of sulfatides and prevent clinical complications. It is not possible for measurement of residual *ARSA* activity in the laboratory using synthetic substrate to predict the disease phenotype. However, the identification of certain mutations in the *ARSA* gene can in some cases predict whether an individual will have a late infantile onset or a later onset. It should be noted that this individual has a later onset of disease than the previously reported patient homozygous for this same mutation, however the previously reported individual had the Pd allele in cis with the p.Pro150Arg mutation [4]. The finding of the Pd allele in cis with another mutation may lower the *ARSA* activity and therefore change the phenotype. The onset and progression of the disease in juvenile and adult patients is very difficult to predict. In the case of newly described mutations or when only found heterozygous in very few patients it may be difficult to determine if the mutation is “severe” or “mild.”

There are limited treatment options for individuals diagnosed with MLD. Recent studies involving autologous hematopoietic stem cell transplantation using virally transduced blood stem cells have been reported [2]. Better outcomes are reported in patients treated before neurologic symptoms are obvious but the long-term success of the approach is still to be determined. Any treatment option relies on rapid and accurate diagnosis of the individual, thus indicating the potential importance of including testing for MLD on the newborn screen. Our case highlights the importance of the need for urine sulfatides and molecular testing if a diagnosis of MLD is suspected.

Supplementary data to this article can be found online at <https://doi.org/10.1016/j.ymgmr.2019.100460>.

Contributions of individual authors

Dr. Kathleen Doherty evaluated the patient and helped develop the primary draft of the manuscript.

Dr. S. Barron Frazier evaluated the patient and helped develop the manuscript.

Dr. Matthew Clark evaluated the patient and helped develop and

revise the manuscript.

Anna Childers served as genetic counselor to the family. She helped to format and revise the final manuscript.

Dr. Sumit Pruthi participated in the care of the patient and included clinical information in the manuscript.

Dr. David Wenger evaluated the lab specimens of the patient, helped establish the diagnosis, and revised and edited the manuscript.

Dr. Jessica Duis evaluated the patient, provided recommendations for genetics work up, helped establish the diagnosis, and compiled, edited and revised the manuscript.

Competing interests

All listed authors have no competing interests to declare.

Details of funding

This research did not receive any specific grant from funding agencies in the public, commercial, or not-for-profit sectors.

Details of ethics approval

Ethics approval was not required given that this was done on a clinical basis in hopes of finding a diagnosis.

Patient consent statement

Proof that informed consent was obtained for publication of this work is available upon request.

Approval from the Institutional Committee for Care and Use of Laboratory Animals: N/A.

Acknowledgements

We would like to thank the patient's family, and we would also like to acknowledge Invitae for providing the images from the data analysis that are provided in the supplementary information.

References

- [1] A. Biffi, M. Cesani, F. Fumagalli, et al., Metachromatic leukodystrophy-mutation analysis provides further evidence of genotype-phenotype correlation, *Clin. Genet.* 74 (2008) 349–357.
- [2] A. Biffi, E. Montini, L. Lorioli, et al., Lentiviral hematopoietic stem cell gene therapy benefits metachromatic leukodystrophy, *Science* 341 (2013) 1233158.
- [3] M. Cesani, A. Capotondo, T. Plati, et al., (2009) Characterization of new arylsulfatase a gene mutations reinforces genotype-phenotype correlation in metachromatic leukodystrophy, *Hum. Mutat.* 30 (2009) E936–E945.
- [4] M. Cesani, L. Lorioli, S. Grossi, et al., Mutation update of ARSA and PSAP genes causing metachromatic leukodystrophy, *Hum. Mutat.* 37 (2016) 16–27.
- [5] V. Gieselmann, I. Krägeloh-Mann, Metachromatic leukodystrophy, in: G.V. Raymond, F. Eichler, A. Fatemi, S. Naidu (Eds.), *International Review of Child Neurology*, Mac Keith Press, London, 2011, pp. 130–155.
- [6] Y. Qu, E. Shapira, R.J. Desnick, Metachromatic leukodystrophy: subtype/phenotype correlations and identification of novel missense mutations (P148L and P191T) causing the juvenile-onset disease, *Mol. Genet. Metab.* 67 (1999) 206–212.
- [7] M.A. Rafi, S. Coppola, S.L. Liu, et al., Disease-causing mutations in cis with the common arylsulfatase A pseudodeficiency allele compounds the difficulties in accurately identifying patients and carriers of metachromatic leukodystrophy, *Mol. Genet. Metab.* 79 (2003) 83–90.
- [8] Y. Weerakkody, Metachromatic leukodystrophy | Radiology Reference Article, Radiopaedia.org Radiopaedia, 2018 Retrieved from: <https://radiopaedia.org/articles/metachromatic-leukodystrophy> (Accessed: 9th March 2018).
- [9] D.A. Wenger, C.A. Williams, Screening for lysosomal disorders, in: F.A. Hommes (Ed.), *Techniques in Diagnostic Human Biochemical Genetics*, Wiley–Liss, New York, 1991, pp. 587–617.