

OPEN

# Trochanteric-sparing Proximal Femoral Resection for Arthritic Spastic Hips

Jennifer M. Bauer, MD, MS,\* Marjorie P. Butler, BS,†  
Perry L. Schoenecker, MD,‡ and Jonathan G. Schoenecker, MD, PhD†§||¶#

**Summary:** Progressive hip subluxation or dislocation leading to degenerative disease, in neuromuscular disease, is a significant cause of morbidity to the patient and burden to the caretaker. Surgical salvage procedures have unpredictable success. We hypothesized that modifying the Castle-type proximal femoral resection by securing a retained greater trochanter with its musculature to the capsular arthroplasty and femoral shaft would compartmentalize the femur to decrease proximal femoral migration and heterotopic ossification (HO), thereby precluding the need for traction and HO prophylaxis while improving pain and caretaker satisfaction. The purpose of this report is to describe the novel trochanteric-sparing proximal femoral resection (TS-PFR) technique. Seventeen hips in 13 patients were treated by the TS-PFR procedure. Twelve of 13 patients experienced complete pain relief, and all had improved sitting tolerance and perineal care. These results represent an improvement from prior salvage operations, without increase in blood loss, length of stay, proximal femoral migration, or HO. One patient underwent revision for failed soft tissue envelope. A retrospective review of patients treated at 2 institutions identified those who underwent TS-PFR for arthritic spastic hip. Perioperative course, radiologic evaluation for migration and HO, and caretaker satisfaction were compared with prior published surgical techniques. The TS-PFR technique is a safe alternative to previously described spastic hip salvage procedures and may improve upon them by creating a compartment for the proximal femur that precludes the need for traction and decreases HO. The technique improves patients' pain, sitting tolerance, perineal hygiene, and caretaker satisfaction.

**Key Words:** neuromuscular spastic hip—trochanteric-sparing proximal femoral resection—Castle resection.

(*Tech Orthop* 2020;35: 51–62)

From the \*Department of Orthopaedics and Sports Medicine, Seattle Children's Hospital, University of Washington, Seattle, WA; †Departments of Orthopaedics and Rehabilitation; §Pharmacology; ||Pathology, Microbiology, and Immunology; ¶Pediatrics; #Vanderbilt Center for Bone Biology, Nashville, TN; and ‡Department of Orthopaedic Surgery, St. Louis Shriners Hospital for Children, Vanderbilt University Medical Center, St. Louis, MO.

J.G.S. is a paid consultant for Orthopediatrics and receives pharmaceuticals for research not related to this study from IONIS pharmaceuticals. The remaining authors declare that they have nothing to disclose.

**For reprint requests, or additional information and guidance on the techniques described in the article, please contact Jonathan G. Schoenecker, MD, PhD, at [jon.schoenecker@vanderbilt.edu](mailto:jon.schoenecker@vanderbilt.edu) or by mail at Departments of Orthopaedics and Rehabilitation, Vanderbilt University Medical Center, 4202 Doctors' Office Tower, 2200 Children's Way, Nashville, TN 37232-9565. You may inquire whether the author(s) will agree to phone conferences and/or visits regarding these techniques.**

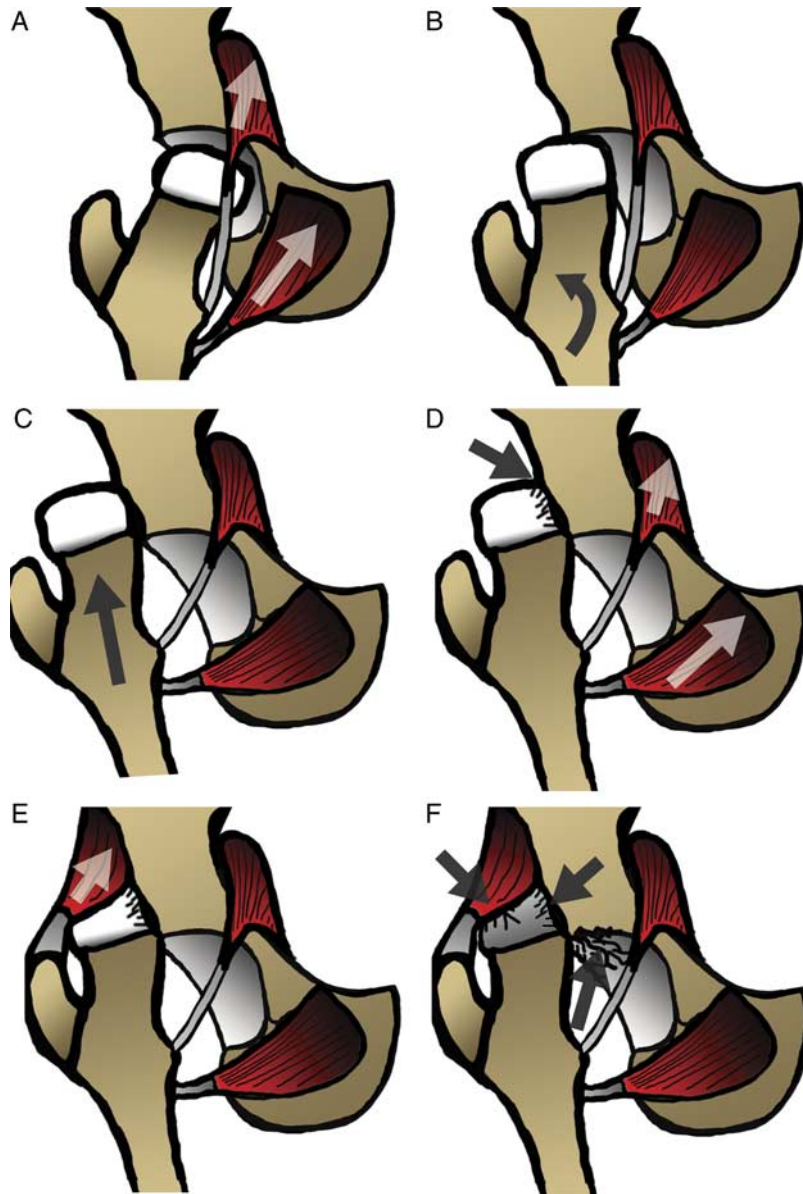
Supplemental Digital Content is available for this article. Direct URL citations appear in the printed text and are provided in the HTML and PDF versions of this article on the journal's website, [www.techortho.com](http://www.techortho.com).

Copyright © 2018 The Author(s). Published by Wolters Kluwer Health, Inc. This is an open-access article distributed under the terms of the Creative Commons Attribution-Non Commercial-No Derivatives License 4.0 (CCBY-NC-ND), where it is permissible to download and share the work provided it is properly cited. The work cannot be changed in any way or used commercially without permission from the journal.

Severe spasticity secondary to static encephalopathy can lead to multiple pathologies including end-stage arthritis of the hip (Fig. 1). The likelihood of hip subluxation, dislocation, and/or arthritis is proportional to the Gross Motor Functional Classification Score (GMFCS) and age.<sup>1</sup> Sixty percent of spastic nonambulators have severely affected hips, ranging from <30% femoral coverage to dislocation,<sup>2</sup> with the average hip dislocation occurring as early as 7 years.<sup>3</sup> The majority of patients (as high as 77%) with spastic neuromuscular hip subluxation or dislocation experience problematic pain and disability.<sup>3–5</sup> Besides causing pain, a subluxated or dislocated hip typically presents with noted difficulties for caretakers with regard to sitting, positioning, perineal hygiene, and diapering.<sup>6</sup> For these reasons, spastic neuromuscular hip instability can be a significant cause of morbidity to the patient and burden to the caretaker.

Treatment of problematic spastic neuromuscular hip dysplasia presenting in late childhood or older is variable. If a congruent and stable reduction can be achieved, there is no marked deformity of the femoral head, and the articular surface is intact, a joint preserving procedure with open reduction and proximal femoral and pelvic osteotomies should be performed.<sup>7–10</sup> If, in contrast, the hip is deemed not salvageable secondary to end-stage arthritis, severe incongruency, or large amount of femoral head bone loss and deformity, several operations exist with the intent of relieving pain and restoring motion necessary for activities of daily living (Fig. 2).<sup>6,11–19</sup> Although morbidity is improved by these procedures, surgeon and caretaker enthusiasm is limited by the need for postoperative traction and reported persistent pain, proximal femoral migration, heterotopic ossification (HO), and high revision rates.<sup>6,11–32</sup>

We hypothesized that altering the proximal femoral Castle and Schneider resection<sup>6</sup> in a novel manner that maintains anatomic location of the muscles surrounding the proximal end of the resected femur would minimize direct muscle injury. Specifically, utilizing technical advances recently developed for surgical hip dislocations described by Ganz et al,<sup>33</sup> we postulated that securing a retained greater trochanter with its attached gluteal and vastus musculature to the capsular arthroplasty and remnant femoral shaft would preclude the need for postoperative traction (Fig. 3 and in more detail below). By compartmentalizing the proximal femur, the rate of later-occurring femoral proximal migration will be reduced. Because injured muscle is the nidus of HO,<sup>34</sup> by maintaining origins and insertions of muscles that cross the hip, we anticipated this technique would minimize Brooker class 3 and 4 HO.<sup>35</sup> The purpose of this study was to describe this technique and the results of the trochanteric-sparing proximal femoral resection (TS-PFR). We will also compare our results to other spastic hip salvage surgeries, as previously published, including the original Castle, McHale, and modified McHale techniques.



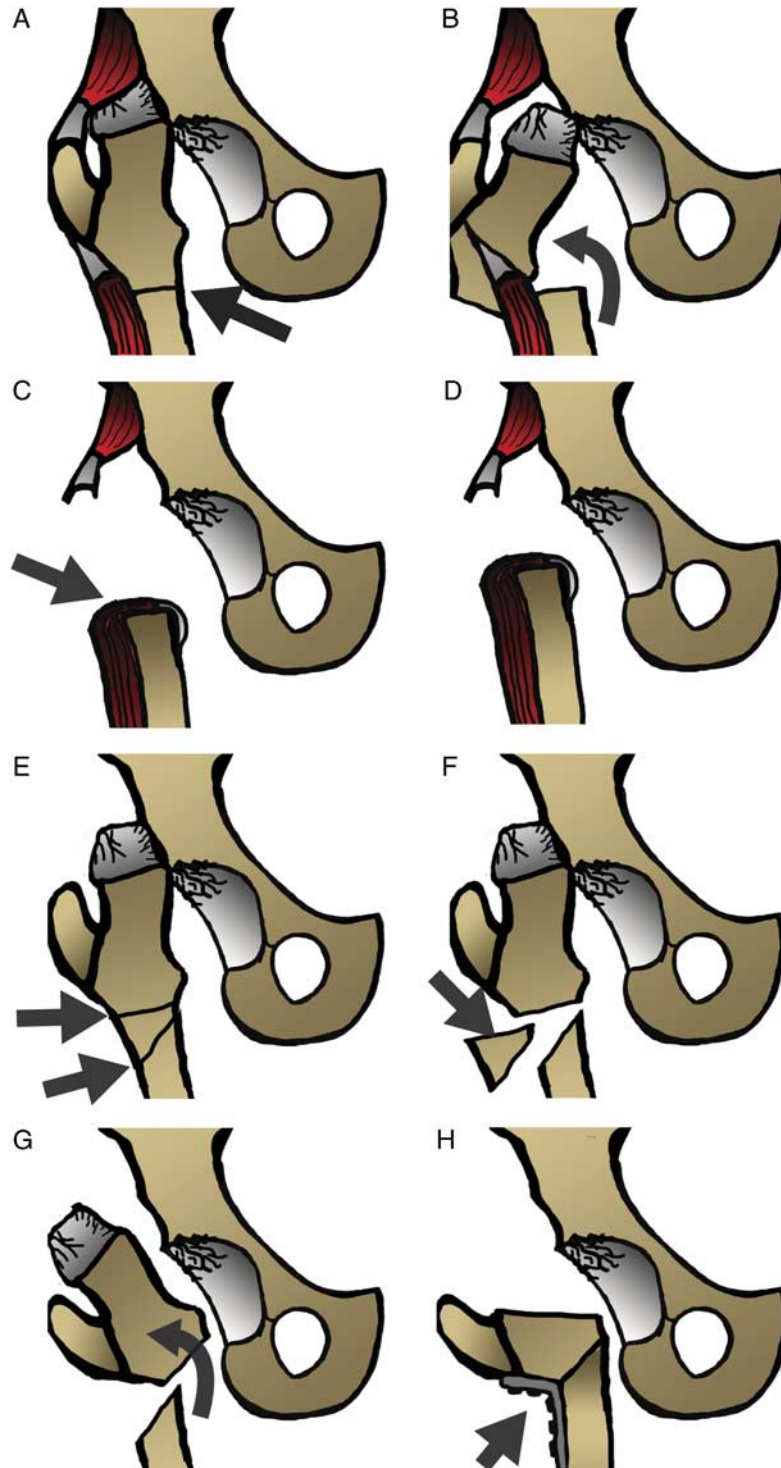
**FIGURE 1.** Spasticity leads to end-stage osteoarthritis in cerebral palsy. Iliopsoas and abductor spasticity (A) leads to femoral head subluxation (B) and dislocation (C). The new position of the femoral head against the supra-acetabular pelvis leads to arthritic degeneration of the femoral head (D), while the overlying gluteus minimum is draped in tension across the proximally-riding femoral head (E). This causes further femoral head deformity with superomedial bone loss (Fig. 7A) and an incongruous head if relocation-reconstructive procedures are performed. The continued spastic motion of the spastic hip adjacent to the acetabulum causes acetabular rim arthritis (F).

**MATERIALS AND METHODS**

After obtaining institutional review board approval, a retrospective chart review was performed for all proximal femoral resections from 2010 through 2015 performed at 2 different pediatric centers. Inclusion criteria included those cases in patients diagnosed as GMFCS IV and V from spastic musculoskeletal disorders that underwent the TS-PFR.

A comprehensive chart review for each subject included basic demographics, musculoskeletal diagnosis, and GMFCS level. Both main and secondary presenting complaints were recorded, along with preoperative pain medications and radiographic hip position.

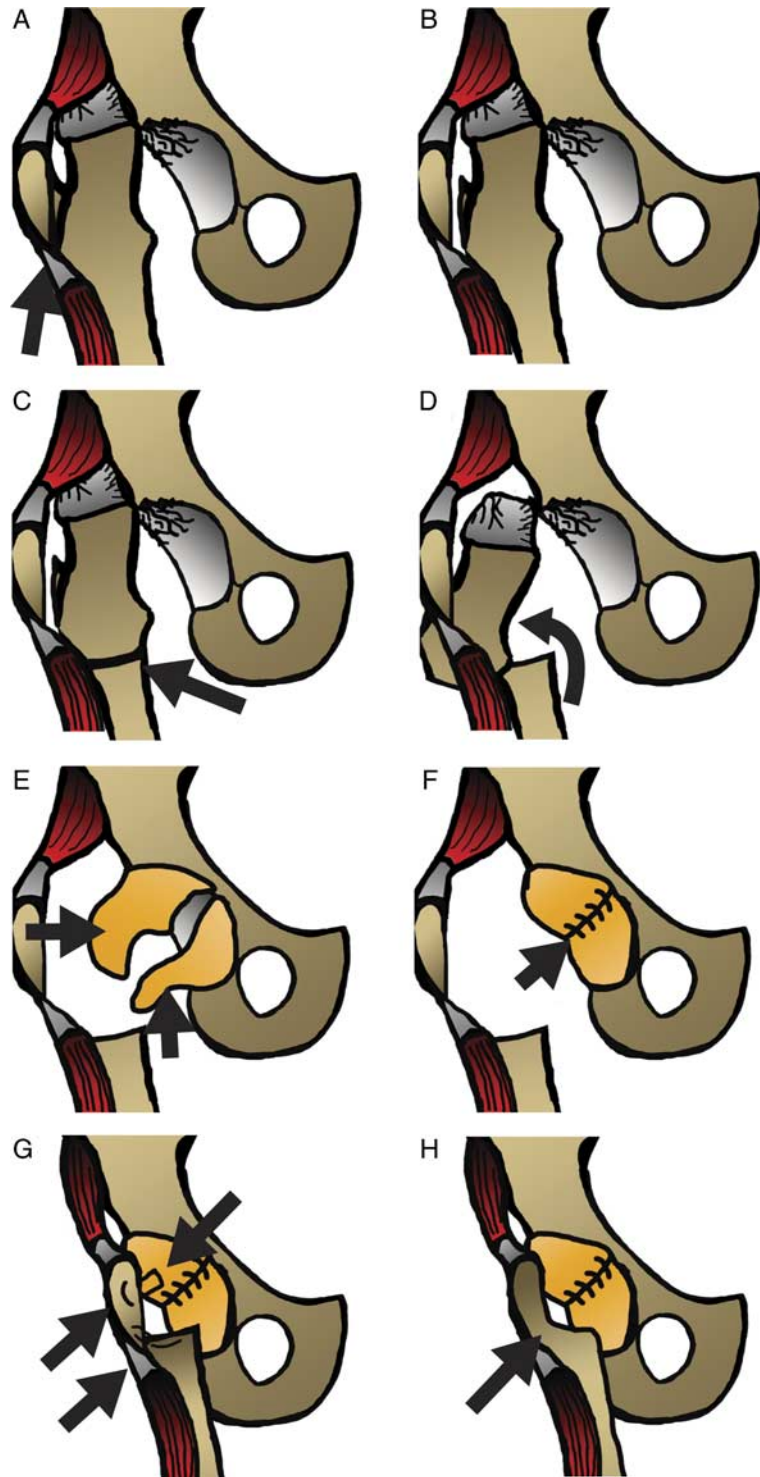
Intraoperative blood loss was averaged between what the anesthesia team and surgeon reported in their operative reports, if found to differ, and divided between 2 hips in bilateral surgery. Estimated blood loss (EBL) was calculated by surgeons’ standard practice, which includes assessing volume in suction canisters and estimating that found on drapes and or packs. Postoperatively, the chart was inspected for the length of stay, immobilization method, and pain medications at the 6-week follow-up. Perioperative radiographs were compared with final follow-up films at last visit to record femoral migration in the technique described by Godfrey et al,<sup>14</sup> who measured the vertical distance between the lateral acetabular roof and the proximal most part of the remnant femoral shaft. This measurement was made in our



**FIGURE 2.** Traditional salvage procedures (A–D, Castle and E–G, McHale). A–D, illustrate the typical Castle procedure. This is a proximal femoral resection that does not include compartmentalization of the femur to decrease heterotopic ossification, nor a restraint to the femoral shaft proximal migration. E–H, Illustrate the McHale procedure. This involves a valgus osteotomy of the proximal femur, with resection of the arthritic femoral head and reliance on osteotomy union with screw and plate implants, without a restraint to the femoral shaft proximal migration.

patients off of the femoral shaft in the same manner, not the retained greater trochanter, as the distinction between the 2 is clear on radiographs and can be extrapolated from initial

radiographs if needed when the trochanter has fully fused. This measurement on postoperative day 0 is compared with final follow-up radiograph to determine migration HO, as classified



**FIGURE 3.** TS-PFR (A–D, resection and E–G, securing). In the TS-PFR, the greater trochanter is osteotomized without releasing the vastus lateralis or gluteus medius attachments (B). A subtrochanteric osteotomy is performed (C), with complete resection of the osteotomized proximal femur (D). The acetabular capsule is then closed (E, F), and the greater trochanter is secured to both the now-closed capsule and the remnant femoral shaft (G) in such a manner that allows union of the greater trochanter to the femoral shaft (H). TS-PFR indicates trochanteric-sparing proximal femoral resection.

according to Brooker et al.<sup>35</sup> All caregivers were surveyed by telephone at the time of midterm data collection and again at final long-term follow-up, using a previously described postoperative

pediatric spastic hip survey,<sup>14</sup> with regard to change in pain, sitting tolerance, perineal hygiene/diapering, and likelihood to recommend the surgery to others.

## Statistical Analyses

Data averages were reported as medians and all confidence intervals (CIs) as 95%. When comparing averages within groups, 1-way analysis of variance was used; when comparing categorical values, chi-squared independence test was used. These were indicated wherever possible for clarity.

TS-PFR is an operative technique (Supplemental Video 1, Supplemental Digital Content 1, <http://links.lww.com/TIO/A15>, “TS-PFR technique”).

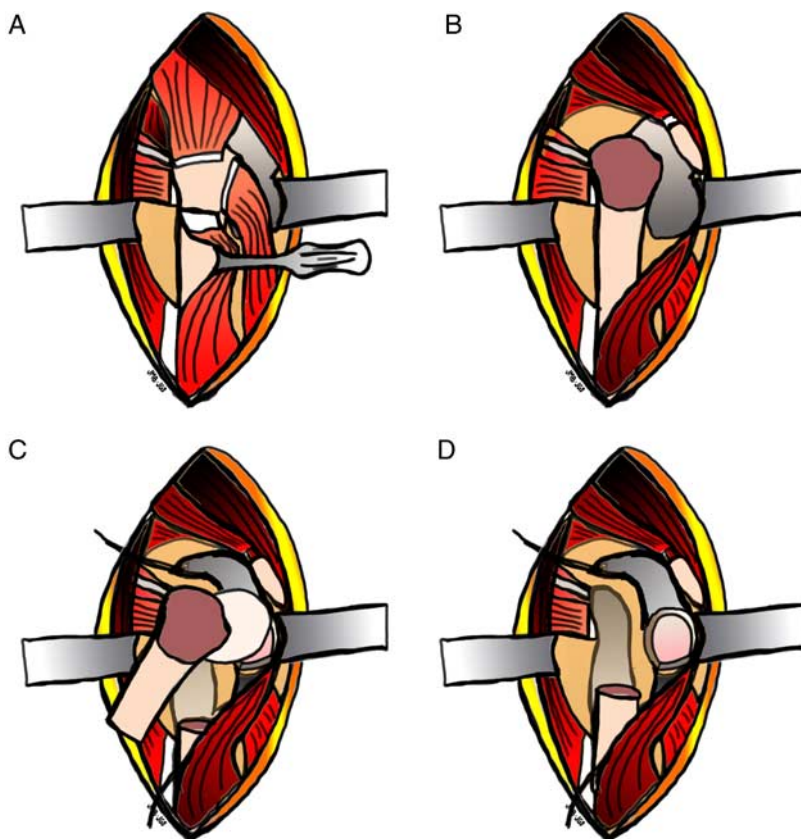
## Approach

Patients are placed in the lateral decubitus position on either a padded peg board or inflatable beanbag, and the involved lower extremity is prepped and draped. The lateral approach is made through a longitudinal incision centered over the greater trochanter, extending distally 4 to 5 cm in line with the femur, and proximally curving posteriorly, as described by Kocher and Langenbeck.<sup>36</sup> The superficial fascial layer is dissected to expose the iliotibial band contiguous with a curvilinear exposure of the gluteus maximus fascia. The iliotibial band is split beginning distally, roughly aligned with the subtrochanteric region of the femoral shaft, and extending proximally through the gluteus maximus fascia, following its curve

posteriorly at the level of the tip of the greater femoral trochanter. A Charnley retractor is placed under the divided fascial layer at the level of the anterior femoral tubercle and short external rotators. The greater trochanteric bursa is excised to expose the vastus lateralis distally, and the external rotators and gluteus medius tendon proximally.

## Trochanteric Osteotomy

The subtrochanteric region of the femur is exposed through a posterior-based subvastus approach, beginning proximally at the level of the vastus lateralis tendon and extending distally to the level of the gluteus maximus insertion (Fig. 4A). A circumferential subperiosteal window is developed using crego elevators immediately distal to the vastus ridge, elevating the vastus tendon anteriorly and linea aspera posteriorly away from the femur. Proximally, the interval between the insertion of the piriformis and the posterior edge of the gluteus medius on the greater femoral trochanter is marked with electrocautery; the fascia and muscle fibers of the gluteus minimus are dissected off the superior border of the piriformis to expose the hip capsule. The gluteal-piriformis interval is extended distally at the planned level of the osteotomy. The osteotomy of the greater trochanter is performed in a posterior to



**FIGURE 4.** Surgical approach and exposure of proximal femur (see text and Supplemental Video 1, Supplemental Digital Content 1, <http://links.lww.com/TIO/A15>, “trochanteric-sparing proximal femoral resection technique” for more detail). A, The proximal femur is exposed through a standard surgical hip dislocation/subvastus approach. The subtrochanteric level is exposed subperiosteally from the vastus lateralis tendon and extending distally to the level of the gluteus maximus insertion. Proximally, the interval between the insertion of the piriformis and the posterior edge of the gluteus medius on the greater femoral trochanter is developed. B, The osteotomized trochanter is then flipped anteriorly, with the gluteus medius/minimus and vastus intermedius/lateralis remaining attached. C, A capsulotomy is performed allowing for complete exposure of the joint. The remaining subtrochanteric region of the femur is subperiosteally dissected, and the femur is osteotomized at or just above the level of the gluteus maximus insertion ~2 to 3 cms distal to the lesser trochanter. D, The proximal femur is resected through subperiosteal dissection, traveling distal to proximal, leaving the periosteum.

anterior direction. It begins proximally between the piriformis and medius tendons, extends distally deep to the vastus tendon, and anteriorly through the anterior tubercle deep into the origin of the vastus medialis, but superficial to the hip capsule, as Ganz originally described in 1998.<sup>37,38</sup> The osteotomized trochanter is then flipped anteriorly, with the gluteus medius/minimus and vastus intermedius/lateralis remaining attached (Fig. 4B). Any remaining gluteus minimus and vastus intermedius are dissected off of the anterior hip capsule to the level of the anterolateral rim of the acetabulum.

### Femoral Resection

A spiked retractor is placed over the anterior rim of the acetabulum just medial and superficial to the reflected head of the rectus tendon. A capsulotomy is performed allowing for complete exposure of the anterior hip joint. The remaining subtrochanteric region of the femur is subperiosteally dissected, and the femur is osteotomized at or just above the level of the gluteus maximus insertion into the elevated linea aspera, ~2 to 3 cms distal to the lesser trochanter (Fig. 4C). The proximal femur is resected through subperiosteal dissection, traveling distal to proximal, and excised (Fig. 4D).

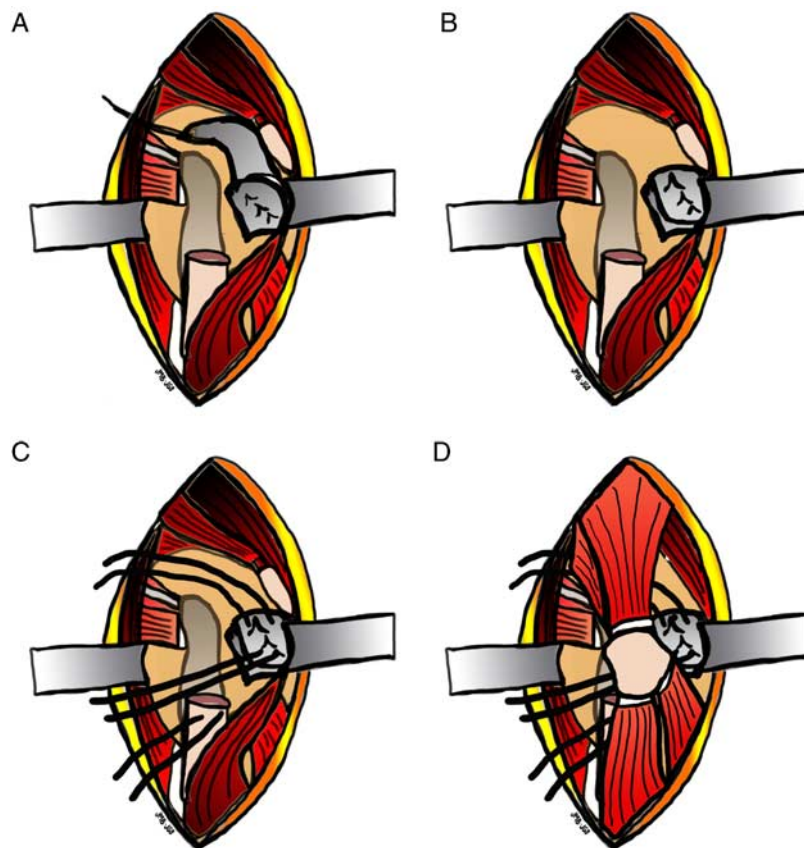
### Compartmentalization

The capsule is imbricated with #2 ethibond sutures (Figs. 5A, B). The trochanter is then affixed simultaneously to the imbricated capsule and remaining femoral shaft with #5 ethibond sutures

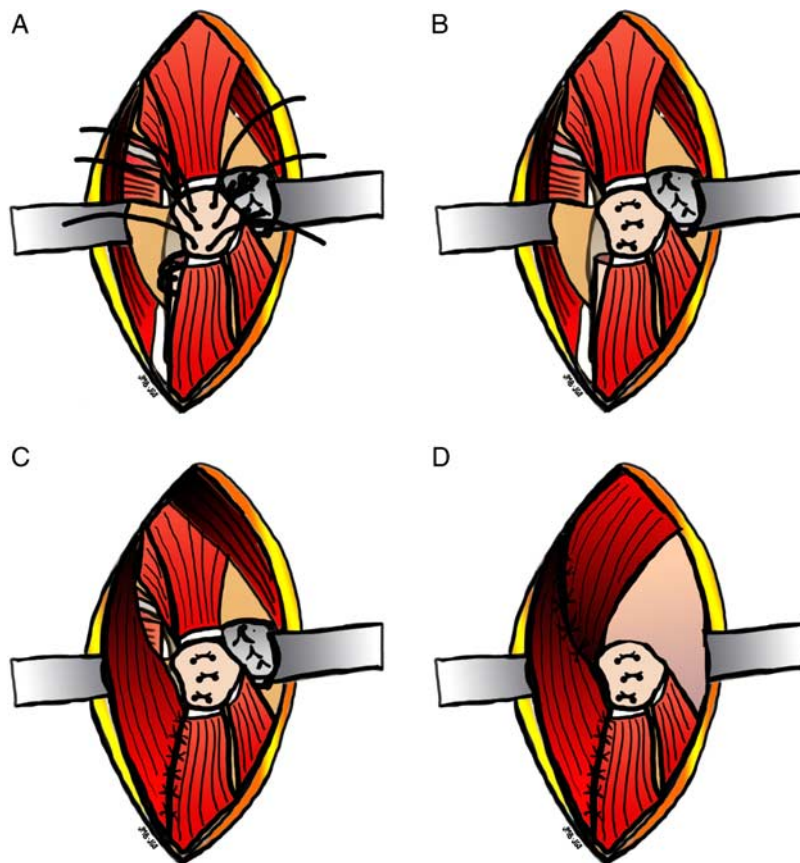
(Figs. 5C, D). Six tunnels are created in the trochanter with a 2.5-mm drill bit (Fig. 6A). All sutures are tied tight, affixing the trochanter to the imbricated capsule by passing 2 different sutures through the top 2 pairs of trochanter tunnels. The distal pair of trochanter bone tunnels is used for the third suture, which is passed from the greater trochanter, through the proximal femur via a bone tunnel with the femur and back through the trochanter to be tied over it (Fig. 6B). The vastus lateralis fascia is repaired to the lateral intermuscular septum, enclosing the remnant femur into the deep compartment of the thigh (Fig. 6C). Repairing the iliotibial band and gluteus maximus fascia enhances the femoral compartment's lateral border (Fig. 6D). Superficial fascia, dermis, and skin are closed with absorbable sutures. The patient is placed into either an abduction pillow, petrie cast, spica cast, or abduction brace for comfort, and allowed activity and transfers immediately as tolerated (Supplemental Video 1, Supplemental Digital Content 1, <http://links.lww.com/TIO/A15>, "TS-PFR technique"). Our preferred immobilization now from experience is an abduction pillow. Patients received postoperative physical therapy for transfer training with the family and seat modifications as needed, and all braces and casts were discontinued at the first 6-week visit.

## RESULTS

Seventeen hips in 13 patients underwent the TS-PFR procedure (Table 1). The youngest patient's surgery was prompted by a failed



**FIGURE 5.** Capsular arthroplasty and preparation of retaining sutures (see text and Supplemental Video 1, Supplemental Digital Content 1, <http://links.lww.com/TIO/A15>, "trochanteric-sparing proximal femoral resection technique" for more detail). The capsule is imbricated to cover the acetabulum with #2 ethibond sutures to form the soft tissue arthroplasty. First the inferior flap (A) then the superior flap (B) over the inferior flap. C, Two sutures (#5 ethibond) are placed through the capsule providing 4 trochanteric-retaining suture limbs. A third suture is passed through 2 holes in the proximal lateral remnant femur providing 2 additional trochanteric-retaining sutures. D, The trochanteric flap segment, with all attached muscles, is placed over the imbricated capsule.



**FIGURE 6.** Compartmentalization (see text and Supplemental Video 1, Supplemental Digital Content 1, <http://links.lww.com/TIO/A15>, “trochanteric-sparing proximal femoral resection technique” for more detail). A, Six passages are placed in alignment with the trochanteric-retaining sutures. The suture ends are drawn through these passages with a Hewson suture passer. B, The sutures are tied. C, The vastus lateralis fascia is repaired to the lateral intermuscular septum, enclosing the remnant femur into the deep compartment of the thigh. D, Repairing the iliotibial band and gluteus maximus fascia enhances the femoral compartment’s lateral boarder. Superficial fascia, dermis, and skin are closed with absorbable sutures (not shown).

**TABLE 1.** Patient Demographics

Demographics	Average (Range)
Age (y)	12.9 (7-32)
Weight (kg)	31.5 (14.5-64)
	N/n
Male/female patients (13 patients)	5/8
Left/right hips (17 hips)	9/8
Patient diagnosis	No. patients (of total N = 13) 12 cerebral palsy 1 incontinentia pigmenti
Patient GMFCS	11: level 5 2: level 4
Chief complaint	No. hips (of total N = 15) 13 pain 1 positioning 1 distal femur fx/immobile hip
Hip position at presentation	11 subluxated 6 dislocated
Prior operation	6 VDRO 6 VDRO 1 McHale

GMFCS indicates Gross Motor Functional Classification Score; VDRO, varus derotation osteotomy.

varus derotation osteotomy that became dislocated and infected. Of the 4 patients who had bilateral procedures, 2 had both hips operated under the same anesthesia, and 2 were staged (1 during the same hospitalization, and the other a year later). Eleven patients were GMFCS level V, and their primary reason for presentation was pain. Five hips’ spasticity was managed with baclofen, 4 with diazepam. One patient was on preoperative narcotics for hip pain. Median follow-up at the time of midterm phone survey was 13.0 months (95% CI, 7.7-19.5 mo), with 8 of 15 hips having at least 12 months of follow-up. Average clinic follow-up was 12.0 months. Final phone survey mean follow-up was 3.3 years (average, 3.4; 95% CI, 2.8-4.0 y).

Median EBL for our patients was 100 mL (95% CI, 56-275). One patient was excluded from EBL data because he had femur fracture fixation under the same anesthesia; this fracture had occurred before surgery during custodial care secondary to contracture and osteopenia associated with spastic hip. The smallest of our cohort, weighing 14.5 kg, required a postoperative blood transfusion. He had undergone staged bilateral resections 4 days apart, with recorded EBL of 100 and 88 mL, respectively. One other patient received a transfusion; she was an outlier with 900 mL EBL, with the next closest EBL at 300 mL.

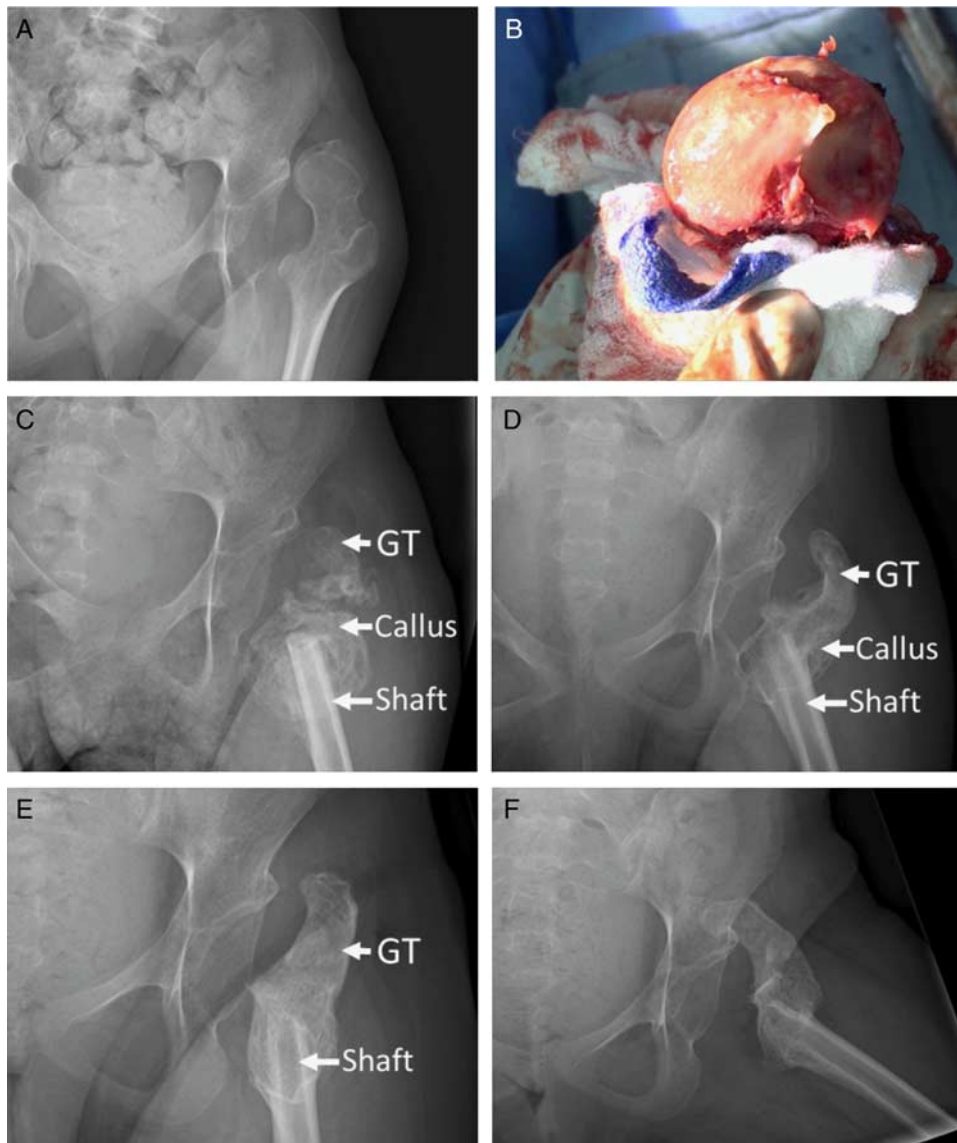
Median length of stay was 3.0 days postoperatively (95% CI, 2.4-5.1). Three outliers stayed 10, 9, and 7 days for postoperative courses complicated by prolonged ileus, PICU transfer for persistent

oxygen desaturations, and feeding intolerance, respectively. There were no other medical complications. Surgical complications included 1 wound cellulitis that resolved following oral antibiotic treatment, and 1 failed soft tissue envelope. In this patient, excessive migration of the proximal femur was noted at the initial 3-week postoperative clinic visit. Treatment consisted of successful revision of soft tissue greater trochanter compartmentalization of the proximal femoral shaft, as it had migrated out of the compartment due to technically poor trochanter fixation to the femur.

Radiographic follow-up revealed 3 distinct healing stages in all patients who had a well-fixed greater trochanter (Fig. 7). Abundant ossification with a woven appearance was first observed in the anatomic location of the remaining cambium layer (see

Fig. 4D and Supplemental Video 1, Supplemental Digital Content 1, <http://links.lww.com/TIO/A15>, “TS-PFR technique” for method of preserving this layer) surrounding the remnant proximal femur and trochanter within 2 months following the procedure (Fig. 7C). Following, the remnant proximal femoral shaft united to the trochanter (Fig. 7D). Finally, the newly formed bone remodeled into mature-appearing bone (Fig. 7E). Exuberant ossification was limited to the areas of remnant periosteum and not within the perihip musculature that would cause arthrodesis (stage 3 or 4 Brooker HO). One patient developed clinically insignificant (no arthrodesis or pain) stage 3 Brooker HO.

Final radiographic follow-up of the cohort, including the single revised patient’s postrevision radiographs, showed no



**FIGURE 7.** Representative preoperative (A), intraoperative gross femoral head specimen showing superomedial bone loss (B), and postoperative progressive healing radiographs (C–F). Thirty-two-year old, nonambulatory woman with chronic spastic subluxation causing pain and caretaker difficulty. Please note labeled greater trochanter and femoral shaft. The labeled callus represents the process of the healing fracture contained within its periosteal compartment, not heterotopic ossification. The periosteum is purposely left to unite the shaft and greater trochanter, like a fracture. Postoperatively the patient reports complete resolution of pain and no difficulty with perineal care (see Supplemental Video 2, Supplemental Digital Content 2, <http://links.lww.com/TIO/A13>, “migration stress” for details of operation).



**TABLE 2.** Proximal Femur Migration

	Abduction Pillow	Petrie Cast	Abduction Brace	Spica Cast	P (ANOVA)
Hips (n)	8	4	3	2	
Migration [median (95% CI)] (mm)	11.5 (4.8-26.4)	6.5 (-5.4 to 23.9)	13.0 (-11.8 to 33.8)	8.0 (-42.8 to 58.8)	0.72
Migration (mean) (mm)	15.6	9.3	11.0	8.0	
Overall mean migration			11.0		

ANOVA indicates analysis of variance; CI, confidence interval.

femoral migration proximal to the acetabulum (Fig. 7 and Supplemental Video 2, Supplemental Digital Content 2, <http://links.lww.com/TIO/A13>, “Migration stress”). Median migration from initial to final postoperative films was 12.4 mm (95% CI [7–19]). No patient required traction, and there was no significant difference in migration between those placed in abduction pillows, petrie casts, abduction braces, or spica casts postoperatively (Table 2). These choices were made by surgeon preference.

Length of stay, EBL, radiographic migration, and complications for the TS-PFR were compared with Godfrey et al’s<sup>14</sup> comparisons of Castle, McHale, and modified McHale procedures (Table 3). Length of stay and EBL values for TS-PFRs are within the range of those for the other 3 procedures that previously found no statistical difference. There is a statistical difference in migration between the groups with a *P*-value <0.05.

Clinical results demonstrated improvement of pain at follow-up for all patients, with no patients using narcotic pain medicine at the 6-week follow-up visit. Because of the resection and subsequent shortening of the femur, all patients regained what would be considered functionally normal hip range of motion. Eleven of 13 patients’ caretakers—representing 15 of 17 hips—were successfully reached by telephone survey at a midterm point of a median of 13 months, and all stated improvement in pain, sitting, and perineal care; furthermore, all would recommend the procedure (Table 4). Ten caretakers—representing 14 of 17 hips—successfully reached at a final follow-up point of a median 3.3 years’ follow-up with some overall decompensation from midterm results including 1 parent who would no longer recommend the procedure (Table 4). This parent added a comment that their child was sitting off to the side and thought having a total hip arthroplasty would have prevented that. One patient who had been wheelchair-bound for many years regained her younger ability of limited household ambulation after surgery (Supplemental

Video 3, Supplemental Digital Content 3, <http://links.lww.com/TIO/A14>, “Ambulation after TS-PFR”). Compared with the other procedures, the TS-PFR shows greater clinical improvement in all categories surveyed (Table 5).

## DISCUSSION

These results indicate that the TS-PFR, “Shen arthroplasty” predictably provides notable relief of what has typically been incapacitating neuromuscular instigated hip pain. In turn, the marked postresection decrease in hip pain allows for an improved ease of care and function in activities of daily living. The structured compartmentalization of the remnant femoral shaft resolves the need for traction without leading to increased migration. Maintaining gluteal and vastus attachments in anatomic locations attached to the trochanteric fragment and periosteal sleeve reduces muscle necrosis, an instigator of HO.<sup>39</sup> Together, these improvements notably increased caretaker satisfaction, as compared with other surgical options. Although final questionnaire satisfaction remained markedly positive, there was a relative decrease seen from initial midterm results. This may represent the natural history of the overall disease process.

Castle and Schneider<sup>6</sup> first described the subtrochanteric proximal femoral resection with soft tissue interposition in 1978, and several studies have followed with minor changes to the soft tissue management. Despite these procedural alterations, the proximal femoral resection requires traction and has been complicated by persistent pain, proximal migration, and/or HO.<sup>11–12,20–27</sup> A modification made by Egermann placed a bone cap on the femur, by using a portion of the osteotomized femoral head, which allowed patients functional return to standing transfers, but still necessitated postoperative traction.<sup>23</sup> As an alternative, McHale proposed a proximal femoral valgus osteotomy that redirects the femoral head away from, and the lesser trochanter towards, the acetabulum. Recent modification

**TABLE 3.** Surgical Comparisons

	Trochanteric-sparing Resection	Castle	McHale	Modified McHale	P
Hips (n)	17	6	8	16	
Average length of stay (d)*	3.7 (1-10)	2.7 (2-4)	3.5 (2-7)	2.9 (1-5)	
Average EBL (mL)*	165 (50-900)	244 (50-255)	244 (50-700)	115 (50-400)	
Average femur migration (mm)*	12.4 (1-38)	32 (10-44)	6 (0-13.5)	12.8 (0.5-46)	0.02 (1-way ANOVA)
Return to OR (revision, infection, hardware removal) (%)	6.7 (1 revision)	33.3 (2 revisions)	25.0 (2 hardware removal)	25.0 (1 revision, 3 hardware removal)	0.44 ( $\chi^2$ independence)

\*Data averages were reported as medians and 95% confidence intervals (CIs).

This group’s trochanteric-sparing proximal femoral resection (column 1) is compared with Godfrey et al’s cohort<sup>14</sup> of patients undergoing the traditional Castle, McHale, and modified McHale procedures.

ANOVA indicates analysis of variance; EBL, estimated blood loss; OR, operation room.

**TABLE 4.** TS-PFR Caretaker Survey, Midterm (Median, 13-mo Follow-up) and Final Follow-up Results (Median, 3.3-y Follow-up)

Hip Subject #	Preoperative Pain (1-10)	Postoperative Pain (1-10)	Pain Resolved?— Completely, Mostly, Somewhat, Minimally		Sitting Tolerance? (h)			Diapering/Perineal care Difficulty?—Very, Somewhat, Little			Would you Recommend to Others?	
			Midterm	Final	Preoperative	Midterm	Final	Preoperative	Midterm	Final	Midterm	Final
1	10	0	Completely	Completely	3	> 3	> 3	Somewhat	Not difficult	Somewhat	Yes	No
2	10	1	Completely	Completely	2	> 3	> 3	Somewhat	Not difficult	Not difficult	Yes	Yes
3	8	0	Completely	Mostly	<1	> 3	> 3	Very	Little	Not difficult	Yes	Yes
4	6	0	Completely	Completely	1	> 6	> 3	Very	Not difficult	Not difficult	Yes	Yes
5	8	1	Completely	Mostly	1	> 3	2	Very	Not difficult	Not difficult	Yes	Yes
6	9	2	Mostly	Mostly	<1	1*	1-3	Very	Not difficult	Not difficult	Yes	Yes
7	10	0	Completely	Mostly	<1	3	1-3	Very	Not difficult	Not difficult	Yes	Yes
8	9	0	Completely	Completely	<1	> 6	> 3	Very	Not difficult	Not difficult	Yes	Yes
9†	10	3	Somewhat		0	0.5		Very	Not difficult		Yes	
10†	10	2	Mostly		0	> 3		Very	Not difficult		Yes	
11	9	1	Completely	Fairly	<1	> 3	1	Not difficult	Not difficult	Not difficult	Yes	Yes

\*Denotes patient whose contralateral hip is spastically subluxated and caretaker is awaiting the same procedure on that side. Caretaker noted on the survey that further sitting tolerance is limited by the contralateral pain.

†Patient 9 lost to follow-up for final follow-up. Patient 10 reached but new foster parent, therefore unable to compare the condition before surgery and after surgery.

TS-PFR indicates trochanteric-sparing proximal femoral resection.

of this procedure also is complicated by persistent pain, proximal femoral migration, and HO.<sup>13–15,28–31</sup> Few have attempted arthroplasty for the GMFCS IV or V patients, which can redislocate or loosen,<sup>15–18,32</sup> or arthrodesis, which can be difficult to unite.<sup>18,19</sup>

In addition to problematic postoperative pain, proximal femoral migration, and heterotopic bone formation (HO) variably occurs. Their occurrence and effect on clinical outcome is controversial, as past reports have been mixed.<sup>20,21,23,27</sup> It is important to note the anatomic location of bone formation

following proximal femoral resections: along remnant periosteum versus within soft tissues. The 2 principle biological tissues that could initiate postresection bone formation are the periosteum and necrotic muscle. In this procedure, periosteal-induced bone formation is permitted by not sacrificing the periosteal sleeve of the resected proximal femur. Given that periosteal bone growth is polarized, with bone forming toward the bone’s cambium layer, and muscle forming outward away from the fibrous layer, we anticipated new bone growth within the confines of the retained periosteum, as it reacts to the osteotomy sites in the same manner as a healing fracture would. Undeniably, most patients developed new bone along the remnant periosteum and often fused the greater trochanter remnant to the femoral remnant, thus restoring the capacity of the trochanteric muscles to mobilize the lower extremity (Supplemental Video 2, Supplemental Digital Content 2, <http://links.lww.com/TIO/A13>, “migration stress”; and Supplemental Video 3, Supplemental Digital Content 3, <http://links.lww.com/TIO/A14>, “ambulation after TS-PFR”). However, this new bone is organized within the compartment that was made for it, therefore also limiting it. We believe that occurrence of problematic HO and associated arthrodesis of the hip joint from Brooker 3 and 4 HO primarily occurs in muscle and surrounding tissues following their release from origin and insertion. We speculated that maintaining insertions and origins of the principle hip musculature would limit the development of HO. Indeed, in this reported cohort, no HO led to difficulty in positioning or diapering, and the one patient with Brooker class 3 HO reported 0 of 10 pain. Although some have advocated for McCarthy et al’s<sup>11</sup> HO classification rather than Brooker et al’s,<sup>35</sup> this procedure purposefully creates McCarthy’s stage

**TABLE 5.** Caretaker Survey Comparison, Final Follow-up Used for TS-PFR

	%			
	Trochanteric-sparing Resection (n = 9)	Castle (n = 4)	McHale (n = 3)	Modified Mchale (n = 6)
Pain improved	100	100	33	83
Perineal care improved	100	100	67	83
Sitting tolerance improved	100*	75	67	50
Recommend this procedure	89	75	33	67

\*Moderate improvement in 2, as detailed above in Table 4. TS-PFR indicates trochanteric-sparing proximal femoral resection.

1 “mushroom cap” over the femur via the retained trochanter, and therefore does not apply to this cohort.

Although this is a multicenter study, a weakness is using comparison groups outside our institutions, which introduces possible confounding variables. However, the survey questions, radiographic measurements, and data recording were all performed in an identical manner. Without raw data from the comparison studies, though, we were unable to perform analysis of variance in some cases, and instead made logical statistical inferences. In addition, there was no documented reasoning behind the chosen immobilization technique for each patient in our cohort. Without a statistically significant difference in femur migration between the different immobilization methods, one may use clinical judgment for what the family and patient might best tolerate.

Borrowing from technical advances used for surgical hip dislocations, TS-PFR for arthritic spastic hip in children may improve on prior salvage operations by precluding the need for postoperative traction, decreasing HO, and leads to improved patient outcomes for pain, positioning, perineal care, and caretaker satisfaction. We have been very encouraged by our results to date with at least a 2.5-year follow-up on all patients. Following treatment with TS-PFR, marked relief of pain post-operatively has been maintained at follow-up, and proximal femoral migration and HO formation have been limited.

## REFERENCES

- Larnert P, Risto O, Hagglund G, et al. Hip displacement in relation to age and gross motor function in children with cerebral palsy. *J Child Orthop*. 2014;8:129–134.
- Howard CB, McKibbin B, Williams LA, et al. Factors affecting the incidence of hip dislocation in cerebral palsy. *J Bone Joint Surg Br*. 1985;67:530–532.
- Samilson RL, Tsou P, Aamoth G, et al. Dislocation and subluxation of the hip in cerebral palsy. Pathogenesis, natural history and management. *J Bone Joint Surg Am*. 1972;54:863–873.
- Cooperman DR, Bartucci E, Dietrick E, et al. Hip dislocation in spastic cerebral palsy: long-term consequences. *J Pediatr Orthop*. 1987;7:268–276.
- Boldingh EH, Jacobs-van Der Bruggen MA, Bos CF, et al. Determinants of hip pain in adult patients with severe cerebral palsy. *J Pediatr Orthop B*. 2005;1:120–125.
- Castle ME, Schneider C. Proximal femoral resection-interposition arthroplasty. *J Bone Joint Surg Am*. 1978;60:1051–1054.
- Mubarak SJ, Valencia FG, Wenger DR. One-stage correction of the spastic dislocated hip. Use of pericapsular acetabuloplasty to improve coverage. *J Bone Joint Surg Am*. 1992;74:1347–1357.
- Sankar WN, Spiegel DA, Gregg JR, et al. Long-term follow-up after one-stage reconstruction of dislocated hips in patients with cerebral palsy. *J Pediatr Orthop*. 2006;26:1–7.
- Root L, Laplaza FJ, Brouman SN, et al. The severely unstable hip in cerebral palsy. Treatment with open reduction, pelvic osteotomy, and femoral osteotomy with shortening. *J Bone Joint Surg Am*. 1995;77:703–712.
- Berglund L, Clohisy JC, Schoenecker P. Treatment of structural instability in the neuromuscular hip. In: Clohisy JC, ed. *The Adult Hip: Hip Preservation Surgery*. Philadelphia: Wolters Kluwer; 2015.
- McCarthy RE, Simon S, Douglas B, et al. Proximal femoral resection to allow adults who have severe cerebral palsy to sit. *J Bone Joint Surg Am*. 1988;70:1011–1016.
- Lampropulos M, Puigdevall MH, Zapozko D, et al. Proximal femoral resection and articulated hip distraction with an external fixator for the treatment of painful spastic hip dislocations in pediatric patients with spastic quadriplegia. *J Pediatr Orthop B*. 2008;17:27–31.
- McHale KA, Bagg M, Nason SS. Treatment of the chronically dislocated hip in adolescents with cerebral palsy with femoral head resection and subtrochanteric valgus osteotomy. *J Pediatr Orthop*. 1990;10:504–509.
- Godfrey J, McGraw J, Kallur A, et al. A modification to the McHale procedure reduces operative time and blood loss. *J Pediatr Orthop*. 2016;36:e89–e95.
- Hogan KA, Blake M, Gross RH. Subtrochanteric valgus osteotomy for chronically dislocated, painful spastic hips. Surgical technique. *J Bone Joint Surg Am*. 2007;89:226–231.
- Buly RL, Huo M, Root L, et al. Total hip arthroplasty in cerebral palsy. Long-term follow-up results. *Clin Orthop Relat Res*. 1993;296:148–153.
- Gabos PG, Miller F, Galban MA, et al. Prosthetic interposition arthroplasty for the palliative treatment of end-stage spastic hip disease in nonambulatory patients with cerebral palsy. *J Pediatr Orthop*. 1999;19:796–804.
- Root L, Goss JR, Mendes J. The treatment of the painful hip in cerebral palsy by total hip replacement or hip arthrodesis. *J Bone Joint Surg Am*. 1986;68:590–598.
- De Moraes Barros Fucs PM, Svartman C, De Assumpcao RM, et al. Treatment of the painful chronically dislocated and subluxated hip in cerebral palsy with hip arthrodesis. *J Pediatr Orthop*. 2003;23:529–534.
- Albiñana J, Gonzalez-Moran G. Painful spastic hip dislocation: proximal femoral resection. *Iowa Orthop J*. 2002;22:61–65.
- Knaus A, Terjesen T. Proximal femoral resection arthroplasty for patients with cerebral palsy and dislocated hips: 20 patients followed for 1-6 years. *Acta Orthop*. 2009;80:32–36.
- Patel NK, Sabharwal S, Gooding CR, et al. Proximal femoral excision with interposition myoplasty for cerebral palsy patients with painful chronic hip dislocation. *J Child Orthop*. 2015;9:263–271.
- Egermann M, Doderlein L, Schlager E, et al. Autologous capping during resection arthroplasty of the hip in patients with cerebral palsy. *J Bone Joint Surg Br*. 2009;91:1007–1012.
- Widmann RF, Do TT, Doyle SM, et al. Resection arthroplasty of the hip for patients with cerebral palsy: an outcome study. *J Pediatr Orthop*. 1999;19:805–810.
- Baxter MP, D'Astous JL. Proximal femoral resection-interposition arthroplasty: salvage hip surgery for the severely disabled child with cerebral palsy. *J Pediatr Orthop*. 1986;6:681–685.
- Abu-Rajab RB, Bennet GC. Proximal femoral resection-interposition arthroplasty in cerebral palsy. *J Pediatr Orthop*. 2007;16:181–184.
- Dartnell J, Gough M, Paterson JM, et al. Proximal femoral resection without post-operative traction for the painful dislocated hip in young patients with cerebral palsy: a review of 79 cases. *Bone Joint J*. 2014;96-B:701–706.
- Leet AI, Chhor K, Launay F, et al. Femoral head resection for painful hip subluxation in cerebral palsy: is valgus osteotomy in conjunction with femoral head resection preferable to proximal femoral head resection and traction? *J Pediatr Orthop*. 2005;25:70–73.
- Wright PB, Ruder J, Birnbaum MA, et al. Outcomes after salvage procedures for the painful dislocated hip in cerebral palsy. *J Pediatr Orthop*. 2013;33:505–510.
- Schejbalova A, Havlas V, Trc T. Irreducible dislocation of the hip in cerebral palsy patients treated by Schanz proximal femoral valgus osteotomy. *Int Orthop*. 2009;33:1713–1717.

31. Hogan KA, Blake M, Gross RH. Subtrochanteric valgus osteotomy for chronically dislocated, painful spastic hips. *J Bone Joint Surg Am.* 2006;88:2624–2631.
32. Koffman M. Proximal femoral resection or total hip replacement in severely disabled cerebral-spastic patients. *Orthop Clin North Am.* 1981;12:91–100.
33. Ganz R, Gill TJ, Gautier E, et al. Surgical dislocation of the adult hip. *J Bone Joint Surg Br.* 2001;83:1119–1124.
34. Peterson JR, Agarwal S, Brownley RC, et al. Direct mouse trauma/burn model of heterotopic ossification. *J Vis Exp.* 2015;102:e52880.
35. Brooker AF, Bowerman JW, Robinson RA, et al. Ectopic ossification following total hip replacement. Incidence and a method of classification *J Bone Joint Surg Am.* 1973;55:1629–1632.
36. Judet R, Judet J, Letournel E. Fractures of the acetabulum: classification and surgical approaches for open reduction. *J Bone Joint Surg Am.* 1964;46:1615–1646.
37. Siebenrock KA, Gautier E, Ziran BH, et al. Trochanteric flip osteotomy for cranial extension and muscle protection in acetabular fracture fixation using a Kocher-Langebeck approach. *J Orthop Trauma.* 1998;12:387–391.
38. Mehlman CT, Meiss L, DiPasquale TG. Hyphenated-history: the Kocher-Langebeck surgical approach. *J Orthop Trauma.* 2000;14:60–64.
39. Mignemi NA, Yuasa M, Baker CE, et al. Plasmin prevents dystrophic calcification after muscle injury. *J Bone Miner Res.* 2017;32:294–308.